

CLINICAL PATHOLOGY

Plantar Fasciitis

A Degenerative Process (Fasciosis) Without Inflammation

Harvey Lemont, DPM*
 Krista M. Ammirati, BS*
 Nesima Usen, MPH*

The authors review histologic findings from 50 cases of heel spur surgery for chronic plantar fasciitis. Findings include myxoid degeneration with fragmentation and degeneration of the plantar fascia and bone marrow vascular ectasia. Histologic findings are presented to support the thesis that "plantar fasciitis" is a degenerative fasciosis without inflammation, not a fasciitis. These findings suggest that treatment regimens such as serial corticosteroid injections into the plantar fascia should be reevaluated in the absence of inflammation and in light of their potential to induce plantar fascial rupture. (J Am Podiatr Med Assoc 93(3): 234-237, 2003)

Plantar fasciitis is presumed to be synonymous with inflammation of the plantar fascia. In fact, the suffix "-itis" inherently implies an inflammatory disease. However, is plantar fasciitis really an inflammatory disorder?

Plantar fasciitis is widely described in the literature as having a multifactorial and widely disputed etiology. Interestingly, in 1965, Lapidus and Guidotti,¹ in their article entitled "Painful Heel," stated that "the name of painful heel is used deliberately in preference to any other more precise etiological diagnosis, since the cause of this definite clinical entity still remains unknown." Now, nearly 40 years later, this statement can still be considered accurate. Although the exact definition of plantar fasciitis varies in the literature, this term is frequently used interchangeably with "heel spur syndrome"² and "painful heel syndrome."³ "Plantar fasciitis" is almost always used to describe a painful heel with inflammation of the plantar fascia at its origin, as opposed to pain originating along the course of the fascia. For example, Hicks⁴ noted that the repetitive excessive loads that

occur with long-distance running may induce an inflammatory process, leading to fibrosis or degeneration, and Sewell⁵ stated that the pain of plantar inflammation may sometimes be secondary to periosteal inflammation of the os calcis. Although authors writing on the subject describe inflammation as being present in plantar fasciitis, they provide no objective clinical or histologic evidence to support their claims. In addition, when photomicrographs are provided, they are often mislabeled as showing inflammation. Lemelle et al,⁶ for example, suggested that inflammation is found in plantar fasciitis, but they provided only photomicrographs of dense fibrous tissue. In all of these cases, the term "inflammation" seems only to be suggested; without any evidence being provided. So, what evidence should be present to establish plantar fasciitis as an inflammatory disorder?

By definition, inflammation is characterized in its acute stage by the classic clinical signs of pain, heat, redness, swelling, and loss of function, and histologically by leukocyte accumulation. In its chronic stage, inflammation is characterized histologically by infiltration with macrophages, lymphocytes, and plasma cells; tissue destruction; and repair involving new vessel proliferation and fibrosis.⁷ Therefore, not only must the cardinal signs of inflammation be observed

*Temple University School of Podiatric Medicine, Philadelphia, PA.

Corresponding author: Harvey Lemont, DPM, Temple University School of Podiatric Medicine, Eighth at Race St, Philadelphia, PA 19107.

clinically, but the classic histologic signs of inflammation should also be present. Typically, however, a diagnosis of plantar fasciitis is established solely by history and elicitation of pain on the plantar aspect of the heel. Radiographic evidence may be included but does not in itself provide evidence of inflammation. Clinical and histologic evidence of inflammation is usually lacking. In contrast, objective evidence is available in the literature to support the presence of degenerative noninflammatory pathologic changes in "plantar fasciitis." Schepers et al⁸ evaluated specimens obtained during plantar heel spur surgery and observed "marked thickening and fibrosis of the plantar fascia at its origin on the medial tubercle." Tountas and Fornasier⁹ also obtained specimens for histologic evaluation from operative resections of the proximal attachment of the plantar fascia and the heel spur, if present, in patients with subcalcaneal pain refractory to conservative treatment. Similarly, examination revealed degeneration of the plantar fascia with no evidence of inflammation. Histologic examination of surgical biopsy specimens in a study by Snider et al¹⁰ showed collagen necrosis, angiofibroblastic hyperplasia, chondroid metaplasia, and matrix calcification. Again, no cellular proof of an inflammatory response was cited.

Also in support of the argument that the changes in plantar fasciitis are noninflammatory, Grasel et al¹¹ examined magnetic resonance images of the plantar fascia in patients clinically diagnosed as having plantar fasciitis. These authors ruled out inflammation as a cause because of the linearity and low prevalence of signal intensity within the fascia. They concluded that the changes noted are best interpreted as per fascial edema due to microtears in the plantar fascia in the area of its insertion into the calcaneus.

Of 10 heel spur samples submitted for pathologic analysis to the Laboratory of Podiatric Pathology at Temple University School of Podiatric Medicine, Philadelphia, Pennsylvania, 10 exhibited normal plantar fascial entheses characterized by a regular transition of bone to fibrocartilage to fascia (Fig. 1), with fibrocartilaginous fibers running parallel to each other (Fig. 2). In addition, 16 samples demonstrated fiber fragmentation in association with myxoid degeneration characterized by basophilic zones of mucopolysaccharide stained positive with alcian blue (pH 2.5) (Fig. 3). In two samples, fascial artifacts and fragmentation in association with crystalline material noted in the area before processing was suggestive of previous corticosteroid injections (Fig. 4).

Approximately 12 of the 16 samples also demonstrated vascularization of the attached bone marrow (Figs. 5 and 6). Low-power cross-sections of bone re-

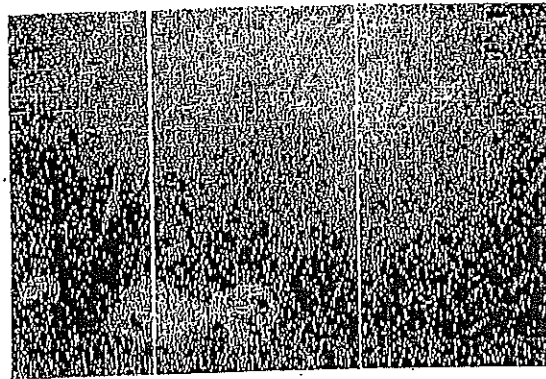


Figure 1. Normal fascial entheses exhibiting metaplasia of bone to fibrocartilage to fascia (H&E, x40).




Figure 2. Fibrocartilage interface between bone and fascia (H&E, x40).

moved from the attachment site demonstrated multiple dilated vessels. Hyperemia may be responsible for the reports of "bone contusion" in patients with heel spurs on T2-weighted images.¹¹ The remaining samples were submitted in sections, preventing adequate pathologic analysis.

In all of the samples reviewed, there was no evidence of inflammation histologically. A review of the literature and the experience of the authors indicate that credible evidence for the assumption that plantar fasciitis is associated with inflammation is lacking. On the other hand, there seems to be substantial evidence that this disorder is associated with degenerative changes in the fascia, which may best be classified as a "fasciosis" rather than fasciitis. This redefinition of plantar fasciitis as plantar fasciosis is warranted from an academic perspective in the same way that posterior tibial tenosynovitis has been reclassified as tendinosis and osteoarthritis has been

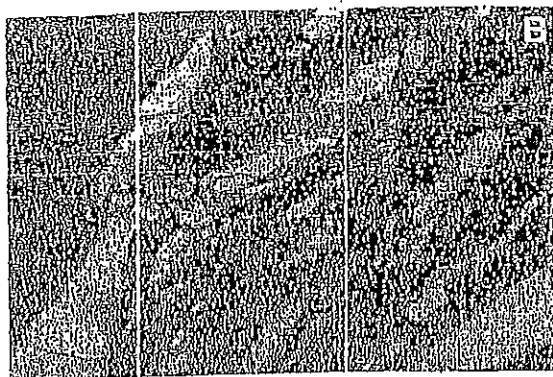


Figure 3. A; Zones of dark-staining areas representing mucopolysaccharide (curved arrows), with degeneration of collagen (straight arrow); B, close-up view of degenerated collagen (fascia) (alcian blue [pH 2.5], $\times 40$).




Figure 4. Artifacts within fascia representing areas of probable previous corticosteroid deposits (H&E, $\times 40$).

reclassified as osteoarthritis. Because principles of management are based on a sound understanding of pathology and physiology, common treatment approaches for "heel spur syndrome" or "plantar fasciitis" should be reexamined. For example, the use of serial corticosteroid injections to control "inflammation" in plantar fasciitis should be questioned and reviewed in the absence of documented evidence of inflammation.

Corticosteroid injections into the region of pain are one of the most common conservative treatments for plantar fasciitis. However, such injections have been associated with serious side effects. Recently, Acevedo and Beskin¹² reported that in a group of 765 patients with a clinical diagnosis of plantar

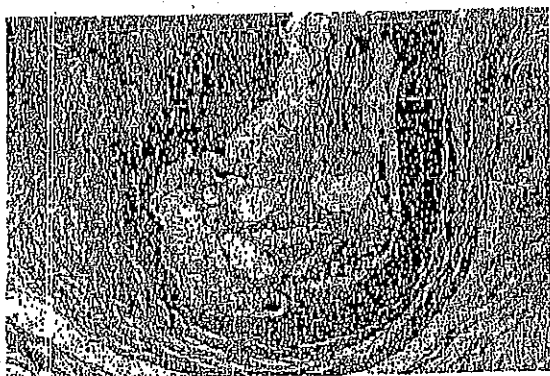


Figure 5. Low-power view of calcaneal marrow demonstrating vascular engorgement (H&E, $\times 20$).




Figure 6. High-power view of calcaneal marrow demonstrating dilated vasculature (H&E, $\times 40$).

fasciitis, 51 were diagnosed as having a plantar fascia rupture. Of these 51 ruptures, 44 (86%) were associated with corticosteroid injection. In another study, Leach et al¹³ reported plantar fascial rupture in five of six athletes previously treated with repeated local injections of a corticosteroid. Moreover, Sellman¹⁴ observed a series of 37 patients with a presumptive diagnosis of plantar fascial rupture and previous heel pain diagnosed as plantar fasciitis and treated with corticosteroid injection into the calcaneal origin of the fascia. One-third of these patients were reported to have rupture of the plantar fascia, described as a sudden tearing episode in the heel, and the remainder described mild-to-moderate pain.

Conclusion

Although corticosteroid injections may be helpful in the treatment of "plantar fasciitis," they may predispose to plantar fascial rupture, and their routine use should be reevaluated, especially in the absence of proof that inflammation exists.

References

1. LAFORD PW, GUDORTH FP: Painful heel: report of 323 patients with 364 painful heels. *Clin Orthop* 30: 173, 1965. Cited by: CAMPBELL W: "Disorders of Tendons and Fascia," in *Campbell's Operative Orthopaedics*, 9th Ed, Vol 2, ed by ST Canale, p 1012, CV Mosby, St Louis, 1996.
2. FULLER BA: The windlass mechanism of the foot: a mechanical model to explain pathology. *JAPMA* 90: 35, 2000.
3. DIMARCANDELO MT, YU TC: Diagnostic imaging of heel pain and plantar fasciitis. *Clin Podiatr Med Surg* 14: 284, 1997.
4. HICKS JH: The mechanics of the foot: part II. The plantar aponeurosis and the arch. *J Anat* 38: 25, 1954. Cited by: SCHEPIS AA, LEACH RE, GORZYOA J: Plantar fasciitis: etiology, treatment, surgical results, and review of the literature. *Clin Orthop* 266: 186, 1991.
5. SEWELL JR: Quantitative scintigraphy in diagnosis and management of plantar fasciitis. *J Nucl Med* 21: 633, 1980. Cited by: SCHEPIS AA, LEACH RE, GORZYOA J: Plantar fasciitis: etiology, treatment, surgical results, and review of the literature. *Clin Orthop* 266: 186, 1991.
6. LEMBLE DP, KISILEWICZ P, JANS LJ: Chronic plantar fascial inflammation and fibrosis. *Clin Podiatr Med Surg* 7: 387, 1990.
7. ROBBINS S: "Acute and Chronic Inflammation," in *Robbins' Pathologic Basis of Disease*, 6th Ed, ed by RS Cotran, V Kumar, T Collins, et al, p 61, WB Saunders, Philadelphia, 1999.
8. SCHEPIS AA, LEACH RE, GORZYOA J: Plantar fasciitis: etiology, treatment, surgical results, and review of the literature. *Clin Orthop* 266: 186, 1991.
9. TOUNTAS AA, FORNASSER VL: Operative treatment of subcalcaneal pain. *Clin Orthop* 332: 170, 1996.
10. SNIDER MT, CLANCY WG, McBEATH AA: Plantar fascia release for chronic plantar fasciitis in runners. *Am J Sports Med* 11: 215, 1983.
11. GRASEL RP, SCHWITZER ME, KOVALOVICH AM, ET AL: MR imaging of plantar fasciitis: edema, tears, and occult marrow abnormalities correlated with outcome. *AJR Am J Roentgenol* 173: 699, 1999.
12. ACEVEDO T, BASKIN JL: Complication of plantar fascia rupture associated with corticosteroid injection. *Foot Ankle Int* 19: 91, 1998.
13. LEACH R, JONES R, SILVA T: Rupture of the plantar fascia in athletes. *J Bone Joint Surg Am* 60: 537, 1978.
14. SELLMAN JR: Plantar fascia rupture associated with corticosteroid injections. *Foot Ankle Int* 15: 376, 1994.